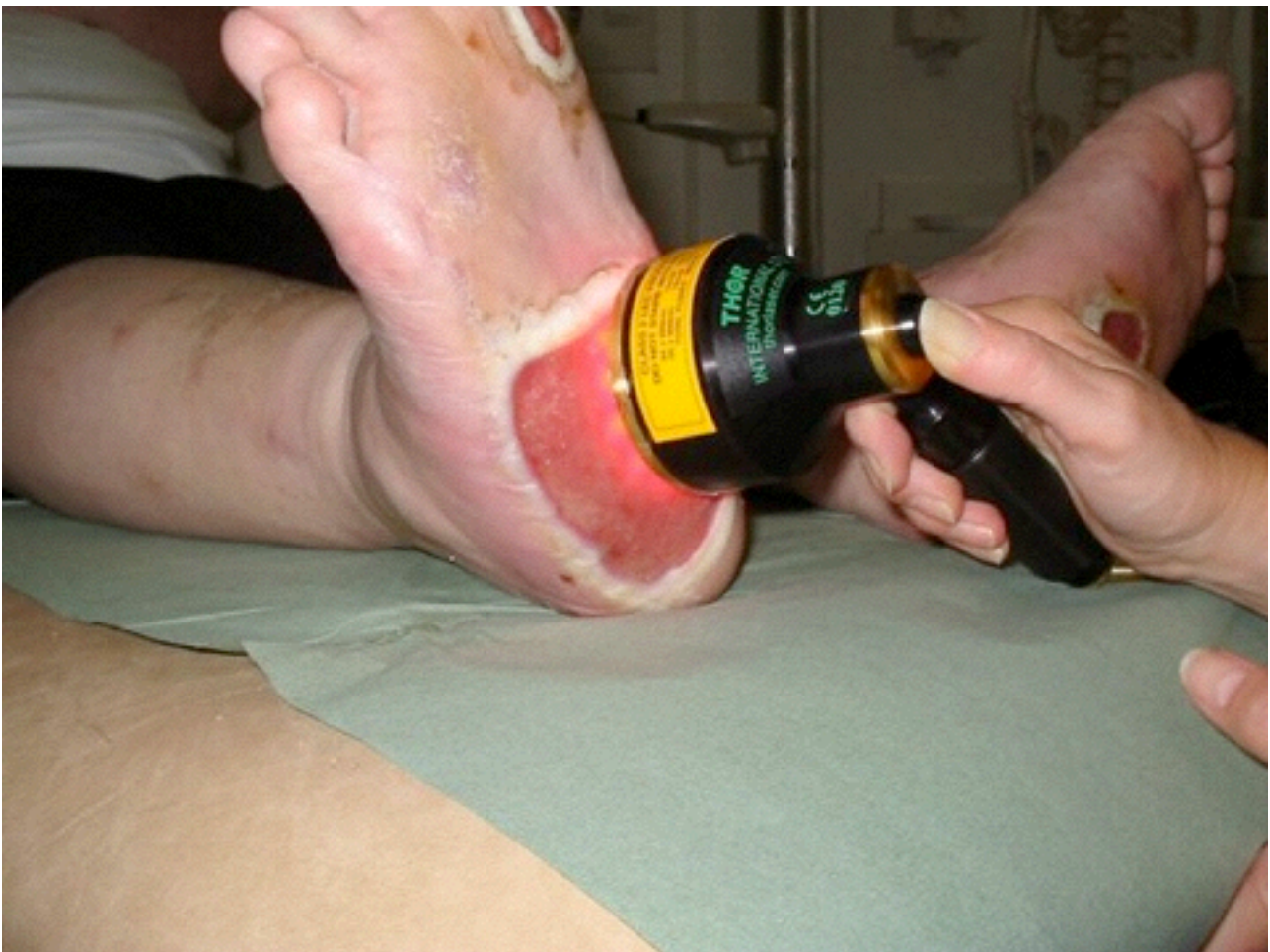

Introduction to Low Level Light Therapy (LLLT)

for wound healing

James D Carroll



Contents

Introduction to Low Level Light Therapy (LLLT) for wound healing	1
Diabetic leg ulcers	2
Venous leg ulcers	7
Pressure ulcers	11
Acute wounds	14
Meta-analysis	15
Inverclyde Royal Hospital review of pressure sore and venous ulcer patients	16

Introduction to Low Level Light Therapy (LLLT) for wound healing

Low Level Light Therapy (LLLT) improves tissue repair, reduces pain and inflammation wherever the beam is applied. Treatments take a few minutes and should be applied two or more times a week.

LLLT has been used for many years on sports injuries, arthritic joints, back and neck pain, and non-healing wounds such as venous ulcers diabetic foot ulcers and pressure sores as well as post chemotherapy and radiation ulcers (mucositis).

How LLLT works

Mitochondria in stressed or ischemic tissues produce nitric oxide (mtNO) that binds to cytochrome c oxidase competitively displacing oxygen leading to oxidative stress and reduced ATP production.

Light of the correct wavelength when applied to wounds is absorbed by cytochrome c oxidase displacing mtNO thereby reducing oxidative stress and increasing ATP production.

A cascade of downstream metabolic effects have been shown to include increased Ca²⁺, secretion of growth factors, activation of enzymes & other secondary messengers.

Subsequent increases in cellular activity and mitosis has been shown in vitro and in vivo including neutrophils, macrophages, fibroblasts, mast cells, endothelial cells and keratinocytes.

Several small clinical trials have shown a significant reduction in healing time and pain in hard to heal wounds.

More information available online

- Website is here www.thorlaser.com
- Download product brochure [here](#)
- Sign up to THOR LLLT Newsletter [here](#)
- Make a purchase enquiry [here](#)
- Download Harvard Medical School review paper [here](#)
- Watch video interviews [here](#)

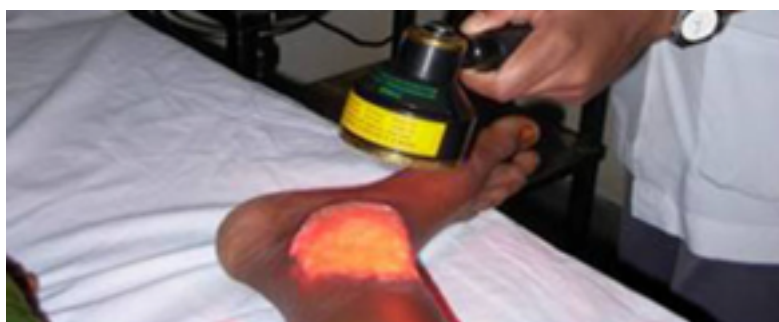Efficacy of Low Level Laser Therapy on Wound Healing in Patients with Chronic Diabetic Foot Ulcers — A Randomised Control Trial.

*Basavaraj M. Kajagar Ashok S. Godhi Archit Pandit S. Khatri
Department of Surgery, Jawaharlal Nehru Medical College, Nehru Nagar,
Belgaum 590 010 Karnataka, India*

Abstract Foot ulcers are serious complications of Diabetes Mellitus (DM) and are known to be resistant to conventional treatment. They may herald severe complications if not treated wisely. Electromagnetic radiations in the form of photons are delivered to the ulcers in laser form to stimulate healing. This study was conducted to evaluate the efficacy of Low Level Laser Therapy (LLLT) in diabetic ulcer healing dynamics. To determine mean percentage reduction of wound area in study and control groups. Settings: KLES Dr. Prabhakar Kore Hospital and Medical Research Centre, Belgaum. Study Design: Randomized-Control Study. Methods: A total of 68 patients with Type 2 DM having Meggitt-Wagner Grade I foot ulcers of atleast more than 4 weeks duration, less than 6×6 cm² with negative culture were studied. Patients were randomized into two groups of 34 each. Patients in study group received LLLT with conventional therapy and those in control group were treated with conventional therapy alone. Healing or percentage reduction in ulcer area over a period of 15 days after commencement of treatment was recorded. Statistical Analysis: Unpaired Student T Test and Mann Whitney U test. Mean age of the patients was 50.94 years in control group and 54.35 years in study group (p 0.065). There was no significant difference between control and study group with respect to mean FBS and HbA1c levels (p > 0.05), suggesting no biochemical differences between two groups. Initial ulcer area was 2608.03 mm² in study group and 2747.17 mm² in control group (p 0.361). Final ulcer area was 1564.79 mm² in study group and 2424.75 mm² in control group (p 0.361). Percentage ulcer area reduction was 40.24 ± 6.30 mm² in study group and 11.87 ± 4.28 mm² in control group (p < 0.001, Z 0.7.08). Low Level Laser Therapy is beneficial as an adjunct to conventional therapy in the treatment of diabetic foot ulcers (DFU).

Indian J Surg. 2012 Oct;74(5):359-63. doi: 10.1007/s12262-011-0393-4.

<http://www.ncbi.nlm.nih.gov/pubmed/?term=24082586>



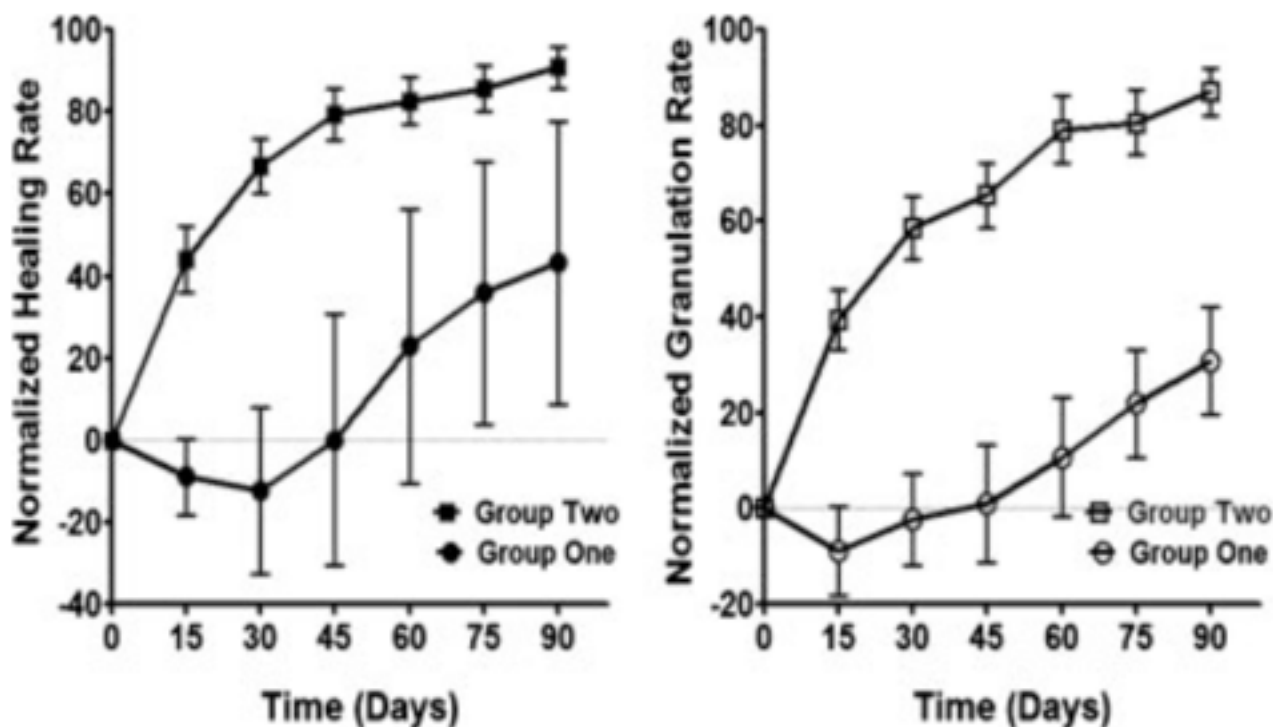
Phototherapy promotes healing of chronic diabetic leg ulcers that failed to respond to other therapies.

Minatel DG, Frade MA, Franca SC, Enwemeka CS

Department of Biotechnology, University of Ribeirao Preto, Ribeirao Preto, Brazil.

OBJECTIVE: We tested the hypothesis that combined 660 and 890 nm LED phototherapy will promote healing of diabetic ulcers that failed to respond to other forms of treatment. **RESEARCH DESIGN AND METHODS:** A double-blind randomized placebo controlled design was used to study 23 diabetic leg ulcers in two groups of 14 patients. Group one ulcers were cleaned, dressed with 1% silver sulfadiazine cream and treated with "placebo" phototherapy ($<1.0 \text{ J cm}^{-2}$) twice per week, using a Dynatron Solaris 705(R) device. Group two ulcers were treated similarly but received 3 J cm^{-2} dose. **RESULTS:** At each of 15, 30, 45, 60, 75, and 90 days of healing, mean ulcer granulation and healing rates were significantly higher for group two than the "placebo" group ($P < 0.02$). While "placebo" treated ulcers worsened during the initial 30 days, group two ulcers healed rapidly; achieving 56% more granulation and 79.2% faster healing by day 30, and maintaining similarly higher rates of granulation and healing over the "placebo" group all through. By day 90, 58.3% of group two ulcers had healed fully and 75% had achieved 90-100% healing. In contrast, only one "placebo" treated ulcer healed fully by day 90; no other ulcer attained $\geq 90\%$ healing. **CONCLUSION:** Combined 660 and 890 nm light promotes rapid granulation and healing of diabetic ulcers that failed to respond to other forms of treatment.

Lasers Surg Med 2009 Aug 41(6) 433-41



Photobiomodulation therapy for diabetic foot ulcers

Moulinath Banerjee, Vivien Wheatland, Jane Humphreys, Patricia Vice

Article points

1. Photobiomodulation therapy involves the application of low-level polychromatic, coherent light to stimulate wound healing, as demonstrated in cell culture, animal and human studies.
2. The closure rates observed in this study suggest a positive role for photobiomodulation therapy in the promotion of healing of diabetic foot ulcers.
3. Any measure that aids closure of diabetic foot ulcers is positive, given the association between ulcers, amputation and morbidity.

Key words:

- Photobiomodulation
- Diabetic foot ulcer
- Wound healing

Moulinath Banerjee is Honorary Clinical Research Fellow at Manchester University, Manchester. Vivien Wheatland and Jane Humphreys are Podiatrists, based at the Royal Preston Hospital, Preston. Patricia Vice is a retired Physician.

A number of studies have suggested that low-level polychromatic, coherent light, described in the clinical setting as photobiomodulation therapy, may improve wound healing. In this retrospective cohort study, photobiomodulation therapy was applied to a series of diabetic foot ulcers as an adjunct to traditional diabetic foot ulcer care. Photobiomodulation therapy was well tolerated by the participants, and a wound closure rate of 48.2% by study end was observed. These results suggest that photobiomodulation therapy may be a beneficial adjunct to traditional treatments for diabetic foot ulcers.

It has been estimated that an ulcer will develop on the foot or ankle of 15% of people with diabetes during their lifetime (Boulton, 2004). Various adjunctive physical therapeutic modalities, including ultrasound, electrotherapy and electromagnetic therapy, have been proposed for the treatment of lower-limb ulcers in people with diabetes (Cullum et al, 2001).

Photobiomodulation therapy is a technique whereby low-level polychromatic, coherent light is applied to injured dermis in an attempt to improve wound healing. The non-thermal effects of light between 1–10 J/cm² on biological tissues has been shown to be beneficial in cell-culture studies (Brondon et al, 2005). Using National Aeronautics and Space Administration developed light emitting diode (LED) technology, Whelan et al (2001) reported in vitro increases in the growth of mouse fibroblasts, rat osteoblasts, rat skeletal muscle cells and human epithelial cells. Using

the same light source, clinical reductions in wound size in rat studies, and reductions in healing time in human volunteers from the US Navy were also reported (Whelan et al, 2001).

Data on the use of photobiomodulation therapy to treat diabetic ulcers are limited. In their review, Forney and Mauro (1999) concluded that further research is required to evaluate the role of lasers and photobiomodulation therapy in diabetic foot ulcer closure.

The retrospective cohort study reported here assessed the efficacy of photobiomodulation using LED (PLED) on the closure of diabetic foot ulcers.

Methods and participants

Twenty people who presented with diabetic foot ulcers between October 2000 and June 2002 at the Royal Preston Hospital were included in this study. Data were taken from podiatry and general medical records.

XXX

The Diabetic Foot Journal Vol 12 No 1 2009

Diabetic neuropathic foot ulcer: successful treatment by low-intensity laser therapy.

Schindl A, Schindl M, Pernerstorfer-Schon H, Kerschan K, Knobler R, Schindl L

Division of Special and Environmental Dermatology, Allergy and Infectious Diseases, University of Vienna Medical School, Vienna, Austria. Andreas.Schindl@akh-wien.ac.at

OBJECTIVE: To evaluate the efficacy of low-intensity laser irradiation for the induction of wound healing of a diabetic neuropathic foot ulcer. **CASE:** We report a case of a man with insulin-dependent diabetes mellitus, sensory neuropathy, macroangiopathy and microangiopathy who had been suffering from an ulcer of his first left toe accompanied by osteomyelitis for 6 weeks. **RESULTS:** After a total of 16 sessions of low-intensity laser therapy using a 670-nm diode laser administered within a 4-week period the ulcer healed completely. During a follow-up period of 9 months, there was no recurrence of the ulcer even though the patient's metabolic condition remained unstable. **CONCLUSIONS:** Although laser therapy was not applied as a monotherapy, the present observation suggests that it might constitute a useful side-effect-free alternative treatment modality for the induction of wound healing of neuropathic ulcers in diabetic patients. Therefore large properly controlled randomized studies seem justified.

Dermatology 1999 198(3) 314-6

Light therapy and advanced wound care for a neuropathic plantar ulcer on a Charcot foot.

Sutterfield R

Christian Hospital NE, St. Louis, Missouri 63136, USA. retta@fidnet.com

Light therapy is a relatively novel modality in wound care. I used a light-emitting diode (LED) and superluminous diode (SLD) to deliver low-intensity laser light as an adjunctive treatment to a patient with a chronic diabetic foot ulcer. Standard treatment of conservative sharp debridement, off-loading, bioburden management, and advanced dressings was delivered in a WOC clinic setting. This combination of therapies resulted in closure of the neuropathic plantar ulcer within 8 weeks.

J Wound Ostomy Continence Nurs 2008 Jan-Feb 35(1) 113-5; discussion 116-7

The use of infrared laser therapy in the treatment of venous ulceration.

*Sugrue ME, Carolan J, Leen EJ, Feeley TM, Moore DJ, Shanik GD
Department of Vascular Surgery, St. James's Hospital, Dublin, Ireland.*

Management of intractable venous ulceration remains an unrewarding task which is increasingly delegated to the realm of the vascular surgeon. The purpose of this pilot study was to assess the ulcer-healing effects of the newest form of biostimulation--the low power laser. Twelve patients with chronic venous ulcers unresponsive to conservative measures were treated with infrared laser irradiation for twelve weeks. Two ulcers healed completely and there was a 27% (p less than 0.01) reduction in size of the remaining ulcers. Treatment resulted in a 44% (p less than 0.01) increase in ulcer floor area occupied by healthy granulation tissue. The most dramatic effect of laser treatment was the reduction in ulcer pain, from 7.5 to 3.5 (linear analogue scale) (p less than 0.001). Laser irradiation had no effect on TcPO₂, number of skin capillaries or pericapillary fibrin deposition in the lipodermatosclerotic area around the ulcer. The results of this pilot study are encouraging and a carefully controlled randomized study is indicated to compare low power laser irradiation to conventional treatment in the management of venous ulcers.

Ann Vasc Surg 1990 Mar 4(2) 179-81

Low Level Laser Therapy in Ambulatory Patients with Venous stasis Ulcers

D. Lichtenstein FICA, B Morag, Maccab

*Health Care Services and Department of Vascular Surgery,
Sourasky Medical Center, Sakler Faculty of Medicine, Tel Aviv Israel*

The effectiveness of Laser Therapy in accelerating wound healing has been clinically well documented. We used two devices: one, a He-Ne laser with a wavelength of 632.8nm and power output of 120mW. The indication for treatment was stasis ulcers (Ulcer cruris) due to chronic venous insufficiency syndrome. Sixty-two patients were treated in this study. The challenge of obtaining good results when treating patients with long-standing vascular ulcers and wounds caused us to explore this technique. We achieved complete healing, classified as good, in 53 patients (85.48%) of the patients during a two week period of treatment, and moderate partial wound closure with clinical improvement in 4 patients (6.46%) with chronic long-term venous leg ulcers. The efficacy of the treatment was (91.94%). No patient had to stop treatment because of adverse side effects. Two patients (3.2%) had recurrent ulcers. These findings indicate that appropriate doses of laser can be beneficial in promoting tissue repair.

Laser Therapy Vol 11 - 2

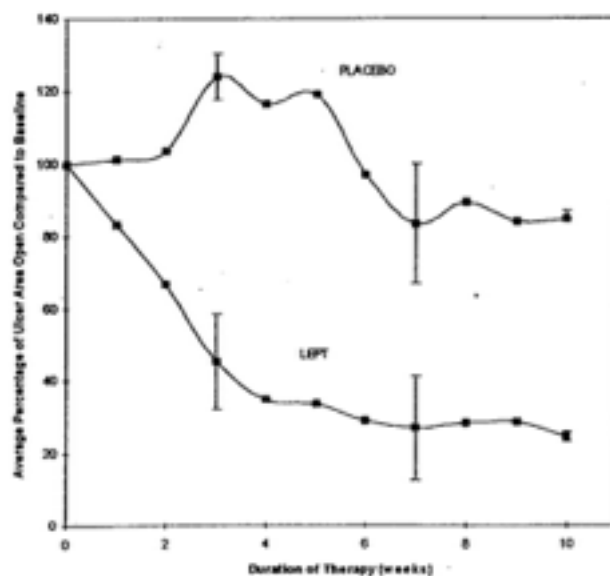
The use of low energy photon therapy (LEPT) in venous leg ulcers: a double-blind, placebo-controlled study.

Gupta AK, Filonenko N, Salansky N, Sauder DN

Department of Medicine, University of Toronto, Ontario, Canada

BACKGROUND: Venous ulcers are estimated to be present in 0.2 to 0.4% of the population. Although new therapies have significant promise, nonhealing ulcers still represent a significant problem. **OBJECTIVE:** To evaluate the efficacy of low energy photon therapy (LEPT) in the treatment of venous leg ulcers. **METHODS:** A placebo-controlled, double-blind study using low energy photon therapy was performed in nine patients with 12 venous ulcers. Treatment was given three times a week for 10 weeks, using two monochromatic optical sources. One source provided a wavelength (λ) of 660 nm (red) while the second source delivered a wavelength of 880 nm (infrared). Two optical probes were used, one consisted of an array of 22 monochromatic sources, operating at a wavelength of 660 nm and covering an area 6 x 10 cm². The second probe had seven infrared sources, operating at a wavelength of 880 nm and covering an area of 4 cm². The above configuration of optical probes was selected to cover the majority of the ulcer area being treated. The patients who were randomized to placebo treatment received sham therapy from an identical-appearing light source from the same delivery system. **RESULTS:** Nine patients with 12 venous ulcers were randomized to receive LEPT or placebo therapy. At the conclusion of the study, the percentage of the initial ulcer area remaining unhealed in the LEPT and placebo groups was 24.4% and 84.7%, respectively ($P = 0.0008$). The decrease in ulcer area (compared to baseline) observed in the LEPT and placebo groups was 193.0 mm² and 14.7 mm², respectively ($P = 0.0002$). One patient dropped out of the study, complaining of lack of treatment efficacy; he was found to be randomized to the placebo group. There were no adverse effects. **CONCLUSION:** In this placebo-controlled, double-blind study LEPT was an effective modality for the treatment of venous leg ulcers.

Dermatol Surg. 1998 Dec 24(12) 1383-6



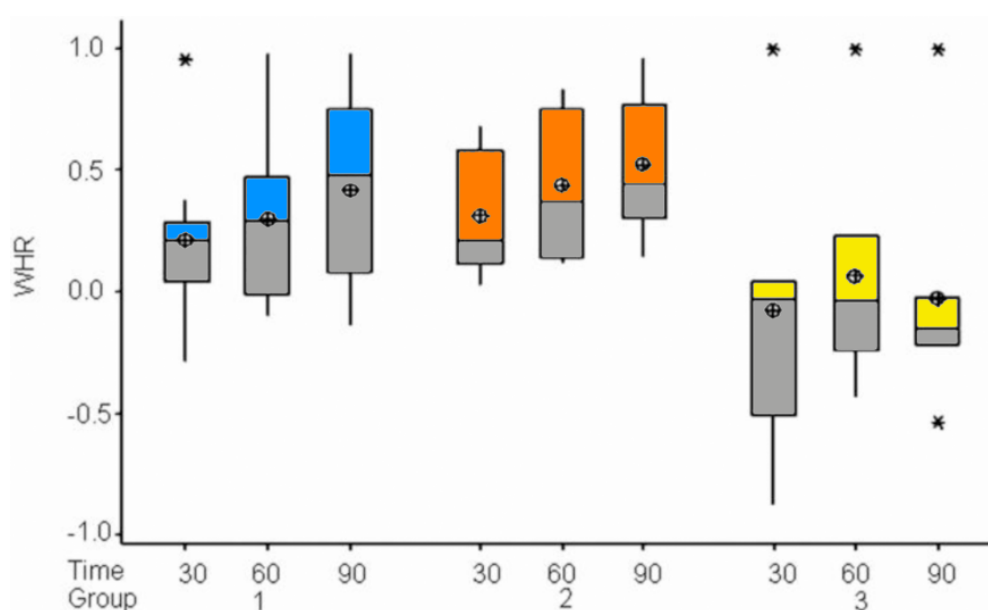
Phototherapy improves healing of chronic venous ulcers

Caetano KS, Frade MA, Minatel DG, Santana LA, Enwemeka CS

Department of Bioengineering, Faculty of Medicine, University of Sao Paulo, Ribeirao Preto, Brazil.

Abstract Objective: We tested the hypothesis that LED phototherapy with combined 660-nm and 890-nm light will promote healing of venous ulcers that failed to respond to other forms of treatment. **Background Data:** A variety of dressings, growth factors, and adjunct therapies are used to treat venous ulcers, but none seems to yield satisfactory results. **Materials and Methods:** We used a randomized placebo-controlled double-blind study to compare a total of 20 patients divided with 32 chronic ulcers into three groups. In group 1 the ulcers were cleaned, dressed with 1% silver sulfadiazine (SDZ) cream, and treated with placebo phototherapy ($<0.03 \text{ J/cm}^2$) using a Dynatron Solaris 705((R)) phototherapy research device. In group 2 the ulcers were treated similarly but received real phototherapy (3 J/cm^2) instead of placebo. In group 3 (controls), the ulcers were simply cleaned and dressed with SDZ without phototherapy. The ulcers were evaluated with digital photography and computer image analysis over 90 d or until full healing was attained. **Results:** Ulcers treated with phototherapy healed significantly faster than controls when compared at day 30 ($p < 0.01$), day 60 ($p < 0.05$), and day 90 ($p < 0.001$), and similarly healed faster than the placebo-treated ulcers at days 30 and 90 ($p < 0.01$), but not at day 60. The beneficial effect of phototherapy was more pronounced when the confounding effect of small-sized ulcers was removed from the analysis. Medium- and large-sized ulcers healed significantly faster with treatment ($\geq 40\%$ rate of healing per month) than placebo or control ulcers ($p < 0.05$). **Conclusion:** Phototherapy promotes healing of chronic venous ulcers, particularly large recalcitrant ulcers that do not respond to conventional treatment.

Photomed Laser Surg 2009 Jan 16



Low level laser therapy in patients with venous ulcers: early and long-term outcome

Kleinman, Y. Simmer, S. Braksma, Y. Morag, B. Lichtenstein, D.

*1:Wound Care Clinic, Department of Internal Medicine, Bikur Holim Hospital, Jerusalem; and
2:Department of Vascular Surgery, Tel Aviv-Sourasky Medical Center, Ichilov Hospital and Sackler
Faculty of Medicine, Israel*

The effectiveness of low level laser therapy in accelerating wound healing has been clinically well documented. We report our experience treating 42 patients with resistant venous ulcers (ulcus cruris) due to chronic venous insufficiency syndrome, using low level laser therapy (LLLT). Full granulation and closure of the ulcers was achieved in 36 patients, two of whom had a recurrence after two years. Complete wound closure in 85.7% of our patients is attributed to the biostimulating effect of laser therapy.

Laser Therapy 1996 Vol 8; Number 3, page(s): 205-208

A case report of low intensity laser therapy (LILT) in the management of venous ulceration: potential effects of wound debridement upon efficacy.

Lagan KM, Mc Donough SM, Clements BA, Baxter GD

Rehabilitation Sciences Research Group, School of Health Sciences, University of Ulster at Jordanstown, BT37 OQB, North Ireland.

OBJECTIVE: This single case report (ABA design) was undertaken as a preliminary investigation into the clinical effects of low intensity laser upon venous ulceration, applied to wound margins only, and the potential relevance of wound debridement and wound measurement techniques to any effects observed. **METHODS:** Ethical approval was granted by the University of Ulster's Research Ethical Committee and the patient recruited was required to attend 3 times per week for a total of 8 weeks. Treatments were carried out using single source irradiation (830 nm; 9 J/cm², CB Medico, Copenhagen, Denmark) in conjunction with dry dressings during each visit. Assessment of wound surface area, wound appearance, and current pain were completed by an independent investigator. Planimetry and digitizing were completed for wound tracings and for photographs to quantify surface areas. Video image analysis was also performed on photographs of wounds. **RESULTS:** The primary findings were changes in wound appearance, and a decrease in wound surface area (range 33.3-46.3%), dependent on the choice of measurement method. Video image analysis was used, but rejected as an accurate method of wound measurement. Treatment intervention produced a statistically significant reduction in wound area using the C statistic on digitizing data for photographs (at Phase one only; $Z = 2.412$; $p < 0.05$). Wound debridement emerged as an important procedure to be carried out prior to measuring wounds. Despite fluctuating pain levels recorded throughout the duration of the study, VAS scores showed a decrease of 15% at the end of the study. This hypoalgesic effect was, however, statistically significant (using the C statistic) at Phase one only ($Z = 2.554$; $p < 0.05$). **CONCLUSIONS:** Low intensity laser therapy at this dosage, and using single source irradiation would seem to be an effective treatment for patients suffering venous ulceration. Further group studies are indicated to establish the most effective therapeutic dosage for this and other types of ulceration.

J Clin Laser Med Surg 2000 Feb 18(1) 15-22

Effects of phototherapy on pressure ulcer healing in elderly patients after a falling trauma. A prospective, randomized, controlled study.

Schubert V.

Karolinska Institutet, Department of Clinical Neuroscience, Occupational Therapy and Elderly Care Research, Huddinge University Hospital, Stockholm, Sweden.

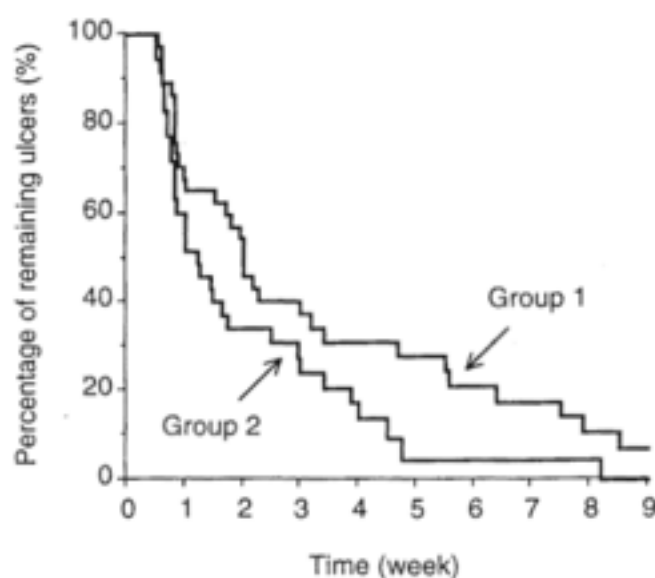
BACKGROUND: The effects of infrared and red pulsed monochromatic light, with varied pulsations and wavelengths, on the healing of pressure ulcers were evaluated in this prospective, randomized, controlled study.

METHODS: Elderly patients (≥ 65 years) with Stage 2 or 3 skin ulcers were enrolled and assigned to one of two groups. Both groups were given the same standard ulcer therapy. One group was also given phototherapy with pulsed monochromatic infrared (956 nm) and red (637 nm) light. Treatments lasted 9 min each time using a regimen with pulse repetition frequency varied between 15.6 Hz and 8.58 kHz. Patients were followed for 10 weeks or until the ulcer was healed, whichever occurred first. The ulcer surface area was traced weekly.

RESULTS: Patients treated with pulsed monochromatic light had a 49% higher ulcer healing rate, and a shorter time to 50% and to 90% ulcer closure compared with controls. Their mean ulcer area was reduced to 10% after 5 weeks compared with 9 weeks for the controls.

CONCLUSION: The results are encouraging as pulsed monochromatic light increased healing rate and shortened healing time. This will positively affect the quality of life in elderly patients with pressure ulcers.

Photodermatol Photoimmunol Photomed 2001 Feb;17(1):32-8



Monochromatic phototherapy: effective treatment for grade II chronic pressure ulcers in elderly patients.

Dehlin O, Elmstahl S, Gottrup F

Department of Community Medicine, Malmo University Hospital, 20502 Malmo, Sweden

BACKGROUND AND AIMS: Monochromatic pulsating light may have effects on wound healing. In an earlier study of grade II ulcers, there was a tendency toward better healing in the phototherapy group ($p=0.06$). The present study on patients with grade II ulcers was performed to verify these findings. Data from this study were pooled with data from the earlier study. **METHODS:** Ninety-four patients were offered participation in the new study and 76 patients were evaluated. They were pooled with 87 patients from the earlier study, bringing the total to 163. All patients were treated with monochromatic pulsating light or placebo over the ulcerated area, according to a specified program up to 12 weeks. **RESULTS:** The mean normalized reduction in pressure ulcer size at week 12 was 0.79 for the phototherapy group and 0.50 for the placebo group (95% confidence interval 0.01-0.53; $p=0.039$). No serious side-effects were noted. **CONCLUSIONS:** Monochromatic pulsating light accelerates healing in grade II pressure ulcers in elderly patients.

Aging Clin Exp Res 2007 Dec 19(6) 478-83

Effect of Laser Irradiation at Different Wavelengths (940, 808, and 658 nm) on Pressure Ulcer Healing: Results from a Clinical Study

J. Taradaj,^{1,2} T. Halski,³ M. Kucharzewski,⁴ T. Urbanek,⁵ U. Halska,³ and C. Kucio⁶

The aim of the study was to assess the efficacy of laser therapy (at different wavelengths: 940, 808, and 658 nm) for treating pressure ulcers. The primary endpoint in this trial included both the percentage reduction of the ulcer surface area and the percentage of completely healed wounds after one month of therapy (ulcer healing rate). The secondary endpoint was the ulcer healing rate at the follow-up evaluation (3 months after the end of the study). In total, 72 patients with stage II and III pressure ulcers received laser therapy once daily, 5 times per week for 1 month using a (GaAlAs) diode laser with a maximum output power of 50 mW and continuous radiation emission. Three separate wavelengths were used for the laser treatment: 940 nm (group I), 808 nm (group II), and 658 nm (group III). An average dose of 4 J/cm was applied. In group IV, a placebo was applied (laser device was turned off). The laser therapy at a wavelength of 658 nm appeared to be effective at healing pressure ulcers. The wavelengths of 808 and 940 nm did not have any effect in our study.

Evid Based Complement Alternat Med 2013 2013 960240

Low intensity laser irradiation in the treatment of recalcitrant radiation ulcers in patients with breast cancer: long-term results of 3 cases.

Schindl A, Schindl M, Pernerstorfer-Schon H, Mossbacher U, Schindl L

Department of Dermatology, University of Vienna Medical School, Austria.

Radiotherapy can be followed by recalcitrant skin ulcers. As low intensity laser irradiation has been demonstrated to have a beneficial effect on impaired wound healing, we investigated its efficacy and safety in three patients with chronic radiation ulcers. The three patients, previously mastectomized due to breast cancer, with recalcitrant radiation ulcers of the skin were treated with a 30 mW helium-neon laser (wavelength: 632.8 nm, intensity: 3 mW/cm², dose: 30 J/ cm²) three times weekly. In all patients, complete wound closure was achieved within a period of 7, 5, and 8 weeks. One patient died 6 weeks after laser treatment due to tumor cachexia. Neither of the other patients showed recurrence of radiation ulcers or neoplasm during a follow-up of 36 months. Low intensity helium-neon laser irradiation has been shown to be effective in the induction of wound healing in radiotherapy-induced ulcers in three patients with breast cancer.

Photodermatol Photoimmunol Photomed 2000 Feb 16(1) 34-7

Increased dermal angiogenesis after low-intensity laser therapy for a chronic radiation ulcer determined by a video measuring system.

Schindl A, Schindl M, Schindl L, Jurecka W, Honigsmann H, Breier F

Department of Dermatology, University of Vienna, Austria.

Acute and chronic radiation-induced dermatitis can occur after high doses of ionizing radiation of the skin. We describe a patient with a long-lasting radiotherapy-induced ulcer that healed after low-intensity laser therapy. A video measuring system was used to determine the number of dermal vessels in the ulcer before and after laser treatment. We found a statistically significant increase in the number of dermal vessels after low-intensity laser therapy in both the central and marginal parts of the ulcer compared with its pretreatment status.

J Am Acad Dermatol 1999 Mar 40(3) 481-4

Low-level laser therapy facilitates superficial wound healing in humans: a triple-blind, sham-controlled study

Hopkins JT, McLoda TA, Seegmiller JG, David Baxter G

Brigham Young University, Provo, UT.

OBJECTIVE: Low-level laser therapy (LLLT) has been promoted for its beneficial effects on tissue healing and pain relief. However, according to the results of in vivo studies, the effectiveness of this modality varies. Our purpose was to assess the putative effects of LLLT on healing using an experimental wound model. **DESIGN AND SETTING:** We used a randomized, triple-blind, placebo-controlled design with 2 within-subjects factors (wound and time) and 1 between-subjects factor (group). Data were collected in the laboratory setting. **SUBJECTS:** Twenty-two healthy subjects (age = 21 +/- 1 years, height = 175.6 +/- 9.8 cm, mass = 76.2 +/- 14.2 kg). **MEASUREMENTS:** Two standardized 1.27-cm(2) abrasions were induced on the anterior forearm. After wound cleaning, standardized digital photos were recorded. Each subject then received LLLT (8 J/cm(2); treatment time = 2 minutes, 5 seconds; pulse rate = 700 Hz) to 1 of the 2 randomly chosen wounds from either a laser or a sham 46-diode cluster head. Subjects reported back to the laboratory on days 2 to 10 to be photographed and receive LLLT and on day 20 to be photographed. Data were analyzed for wound contraction (area), color changes (chromatic red), and luminance. **RESULTS:** A group x wound x time interaction was detected for area measurements. At days 6, 8, and 10, follow-up testing revealed that the laser group had smaller wounds than the sham group for both the treated and the untreated wounds ($P < .05$). No group x wound x time differences were detected for chromatic red or luminance. **CONCLUSIONS:** The LLLT resulted in enhanced healing as measured by wound contraction. The untreated wounds in subjects treated with LLLT contracted more than the wounds in the sham group, so LLLT may produce an indirect healing effect on surrounding tissues. These data indicate that LLLT is an effective modality to facilitate wound contraction of partial-thickness wounds.

J Athl Train 2004 Sep 39(3) 223-229

The efficacy of laser therapy in wound repair: a meta-analysis of the literature.

Woodruff LD, Bounkeo JM, Brannon WM, Dawes KS, Barham CD, Waddell DL, Enwemeka CS

Department of Physical Therapy, North Georgia College and State University, Dahlonega, Georgia, USA.

OBJECTIVE: We determined the overall effects of laser therapy on tissue healing by aggregating the literature and subjecting studies meeting the inclusion and exclusion criteria to statistical meta-analysis. **BACKGROUND DATA:** Low-level laser therapy (LLLT) devices have been in use since the mid sixties, but their therapeutic value remains doubtful, as the literature seems replete with conflicting findings. **MATERIALS AND METHODS:** Pertinent original research papers were gathered from library sources, online databases and secondary sources. The papers were screened and coded; those meeting every inclusion and exclusion criterion were subjected to meta-analysis, using Cohen's d. statistic to determine the treatment effect size of each study. **RESULTS:** Twenty-four studies with 31 effect sizes met the stringent inclusion and exclusion criteria. The overall mean effect of laser therapy on wound healing was highly significant ($d = +2.22$). Sub-analyses of the data revealed significant positive effects on wound healing in animal experiments ($d = +1.97$) as well as human clinical studies ($d = +0.54$). The analysis further revealed significant positive effects on specific indices of healing, for example, acceleration of inflammation ($d = +4.45$); augmentation of collagen synthesis ($d = +1.80$); increased tensile strength ($d = +2.37$), reduced healing time ($d = +3.24$); and diminution of wound size ($d = +0.55$). The Fail-Safe number associated with the overall effect of laser therapy was 509; a high number representing the number of additional studies-in which laser therapy has negative or no effect on wound healing-required to negate the overall large effect size of +2.22. The corresponding Fail-Safe number for clinical studies was 22. **CONCLUSION:** We conclude that laser therapy is an effective tool for promoting wound repair.

Photomed Laser Surg 2004 Jun 22(3) 241-7

The use of low level laser therapy as a treatment for chronic wounds

Lydia Jack is Tissue Viability Nurse Specialist,
Inverclyde Royal Hospital, Greenock, Scotland

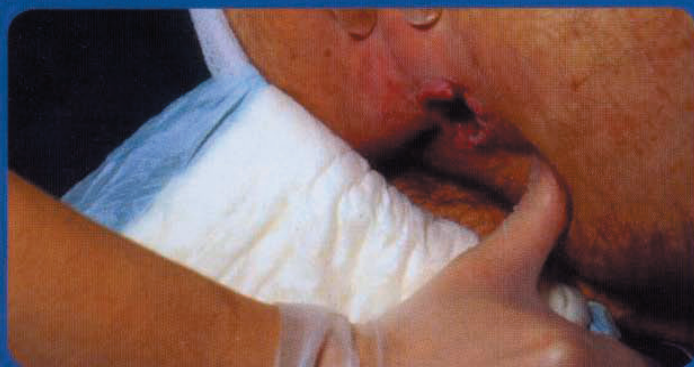

Figure 1. A stage 4 pressure sore in a 49-year-old male before commencing laser therapy.

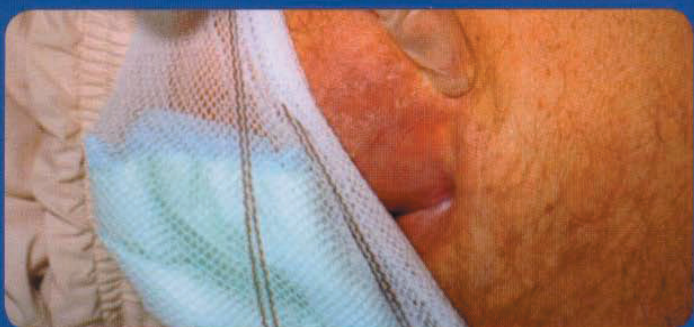


Figure 2. The 49-year-old male is fully healed following 7 months of treatment.

Laser therapy is the application of a narrow spectral-width light over injuries or lesions to stimulate healing. It has been found to improve wound-healing rates, and reduce pain and the risk of infection (Gupta et al, 1998). Laser therapy has been used to treat arterial and venous leg ulcers, pressure ulcers, and burns, as well as infected, traumatic and postoperative wounds that are failing to heal (Kleinman et al, 1996).

The effects of laser therapy are photochemical and not thermal. The suggested mechanism of action is that photons or light cells from a laser treatment probe are absorbed into the cell mitochondria. The absorption of the

photonic energy leads to the stimulation of cellular metabolism. The absorbed energy is then transferred to other molecules, causing chemical reactions in the surrounding tissues (Dyson et al, 2002).

Small amounts of singlet oxygen build up as a result of the absorption of photons. Singlet oxygen is a biochemical intermediate that influences the formation of adenosine triphosphate (ATP). Cell membrane permeability is affected and proton gradients are formed, affecting calcium, sodium, and potassium ions, and allowing ATP to be synthesised and deoxyribonucleic acid (DNA) to be produced. This process also increases photo-acceptor activity on the cell

membrane. This cascade of events results in faster resolution of the inflammatory response, reduction of pain and increased tensile strength, leading to improved tissue repair (Dyson, 2002).

Case study I

Mr X is a 49-year-old man with multiple sclerosis. He is wheelchair bound but enjoys a good quality of life. He was referred to the tissue viability service by a consultant surgeon for dressing advice on a stage 4 pressure ulcer. He had had the ulcer, which was on his buttock, for over 2 years and was being treated by the district nurses.

On examination, the pressure ulcer was approximately 4 x 6 cm at the wound surface but with a cavity extending for 6 cm (Figure 1). The district nurses had been packing the cavity and dressing the wound with appropriate conventional dressings; Aquacel (ConvaTec, Middlesex) and Tielle Plus (Johnson and Johnson Wound Management, Ascot). Mr X had been supplied with a pressure-relieving mattress that was adequate for his needs. The only change to his care package initiated on his referral related to his seating regime; his current cushion was renewed and upgraded. Given that his existing care was appropriate, yet his ulcer hadn't healed, the decision was taken to add laser therapy to his treatment regime.

Mr X attended the outpatient clinic twice weekly for laser therapy and dressing changes. Laser therapy was commenced using a size 69 LED cluster probe (Thor International Ltd, Amersham, Buckinghamshire). First, it was necessary to promote granulation in the cavity. This was done in line with the manufacturer's recommendations to treat the area immediately above the cavity at skin level. The treatment time was one minute per cluster at a frequency of 20 Hz. This initially took a total of 3 minutes, needing less time as the wound healed and thus the area needing treatment diminished.

Within 5 weeks of treatment the tracking area had decreased to 3 cm. Once the tracking area had granulated the entrance of the wound was then treated by applying the cluster probe directly on to the wound. The pressure ulcer was fully healed after 7 months of treatment (Figure 2) and has remained so.

Case study 2

Mr Y is a 56-year-old man with a complex medical history, including hypertension. He is also an overweight non-insulin-dependent diabetic with peripheral neuropathy, and an ex-smoker, having previously smoked 40 cigarettes per day.

Mr Y had leg ulcers for a period of 16 years. Following a vascular review he was commenced on compression therapy. This treatment continued until he had a bilateral skin graft. However, approximately 5 months post-surgery, he developed two ulcerated areas on one leg (Figure 3). The district nurses treated him for several months with a conventional, appropriate dressing regimen, until he was re-referred to the vascular clinic and again commenced on compression therapy.

Following an angiogram, it was suggested that a revascularisation procedure would be necessary; however, in view of his weight, it was decided to continue with conservative treatment. At this point the vascular nurse referred him to the tissue viability service for laser therapy.

On examination, Mr Y was found to have two ulcerated areas on his right leg, one being 1.5 x 1 cm and the other 0.5 x 0.5 cm; both were granular in nature. The dressing regime of Allevyn (Smith and Nephew, Hull) was not changed as it was considered to be providing the warm, moist environment necessary for wound healing (Winter, 1962). Another reason for not changing his current treatment was to assess

whether the laser therapy had any effect on the ulcers.

Laser therapy was commenced, using a size 69 LED cluster probe. In order to treat the ulcers and the surrounding skin, the standard regime of one cluster to each ulcerated area, for a treatment time of one minute at a frequency of 20 Hz, was begun.

Following four treatments over 4 weeks, the smaller ulcer was fully healed (Figure 4) and the patient was advised to apply simple moisturiser to ensure that the skin remained in good condition.

By 11 treatments, just under 6 weeks, the remaining ulcer had decreased in size and was measuring 0.6 x 0.4 cm. The ulcer continued to improve and by treatment 17 (17 weeks) the ulcer was healed. Both ulcers have remained healed.

Conclusion

Before the introduction of laser therapy to their plan of care, the above two

patients were having optimal conventional treatment with minimal success. Following the addition of laser therapy to the existing conventional treatment, the wounds of both patients progressed to full healing. The author is now running a successful laser clinic and has successfully treated a variety of chronic wounds including venous and arterial leg ulcers, pressure ulcers, pilonidal sinuses, traumatic wounds and burns. The laser is simple to use and very cost-effective in terms of finance and time, but more importantly, improves the quality of life for some patients. **WJL**

Dyson M, Agailby A, Ghali L (2002) *Lasers Med Sci* 17(4): A22

Gupta AK, Filonenko N, Salansky N, Sauder DN (1998) The use of low energy photon therapy (LEPT) in venous leg ulcers: a double-blind, placebo-controlled study. *Dermatol Surg* 24(12): 1383-6

Kleinman Y, Simmer S, Braksma Y et al (1996) Low level laser therapy in patients with diabetic foot ulcers: early and long term outcome. *Laser Ther* 8: 205-8

Winter GC (1962) Formation of scab and the rate of epithelialisation of superficial wounds of the young domestic pig. *Nature* 193: 293-4

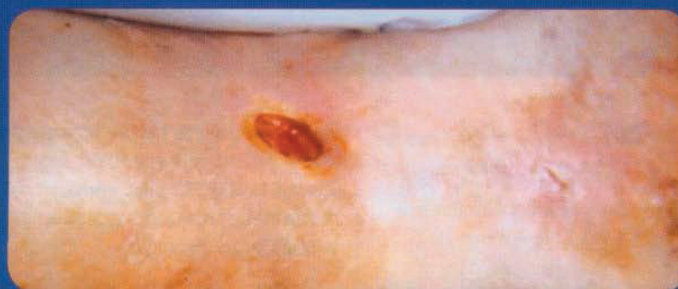

Figure 3. A venous leg ulcer in a 56-year-old man with diabetes before laser treatment.

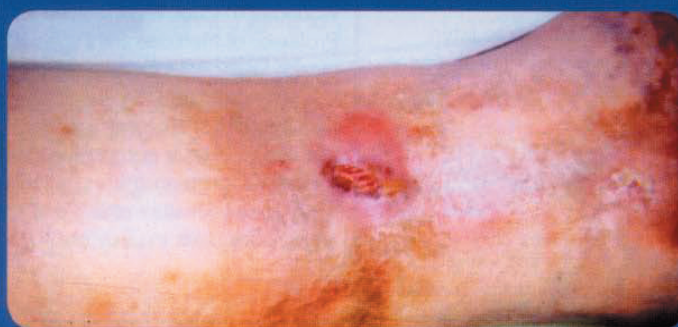

Figure 4. A venous leg ulcer following 11 treatments with laser therapy.